

OCCURENCE OF *DIROFILARIA SPP.* IN DOGS IN LATVIA (2008- 2011)

Linda Stepanjana¹, Dina Cirule¹, Muza Kirjusina²

¹Pathology division, Institute of Food safety, Animal Health and Environment - “BIOR”, Latvia

²Institute of Systematic Biology, University of Daugavpils, Latvia
linducis21@gmail.com

ABSTRACT

The study was carried out from 2008 to 2011. A total 4122 samples of domestic dog's blood were investigated from Riga and Riga's vicinity and regions of Latvia. Overall, 3% (125) samples were positive for the presence of *Dirofilaria* spp. Blood smear microscopy and KNOTT test for *Dirofilaria* spp. larva detection were used in this study. All samples were analysed by following parameters: results of parasitological investigation of bloods smears, year of investigation, season, and age of animal and breed of dog. One human case of *Dirofilaria repens* infection was recorded in Latvia in 2010.

KEY WORDS: dog, *Dirofilaria* spp. distribution.

INTRODUCTION

Dirofilaria spp. has spread to nearly all locations where its vector, the mosquito, is found now. Transmission of the parasite occurs in all of the United States (cases have even been reported in Alaska), and the warmer regions of Canada. The highest infection rates are found within 150 miles of the coast from Texas to New Jersey, and along the Mississippi River and its major tributaries. It has also been found in South America, southern Europe, Southeast Asia, the Middle East, Australia, Korea, and Japan. The global warming and the climate change may promote the expanding of distribution range of *Dirofilaria* spp. to areas they had never found before (Rafiee, 2000; Tarello, 2011; Taylor, 1987).

Dirofilaria repens a filarial nematode of dogs, cats and other carnivores can accidentally infect humans, caused by the bites of mosquito. *D. repens* usually localize in the subcutaneous tissue. The combined action of adults and microfilariae causing immunosuppression, contribute to the manifestation of itching and dermatological signs. Cutaneous signs are caused by capillary embolization of microfilariae, movement of adults in the subcutaneous tissues, auto- immune- allergic reactions to microfilariae and toxins released by the parasites. Skin symptoms affected dogs show local scratching, licking and biting and become progressively severe, cause self traumatic lesions. The main clinical signs are conjunctivitis, anorexia, vomiting, fever and lethargy (Anderson, 2000; Marty, Neafie, 2000; Pampiglione, Rivasi, 2000; Zincenko, Krumina, Cirule, Stepanana, Kirjusina, 2012).

Dirofilaria immitis is a parasitic roundworm, called heartworm, that is spread from host to host through the bites of mosquitoes. The definitive host is the dog, but it can also infect cats, wolves, coyotes, foxes and other animals, such as ferrets, sea lions and other. The main localization of *Dirofilaria immitis* is pulmonary arterial system (lung arteries), and the primary effect on the health of the animal is a damage to the lung vessels and tissues (Anderson, 2000; Merck Veterinary Manual, 2006; Pampiglione, Rivasi, 2000; Zincenko, Krumina, Cirule, Stepanana, Kirjusina, 2012).

The main vectors of the parasite are mosquitos' of genus *Anopheles*, *Aedes* and *Culex*.

Adult worms cannot reach maturity in the human body. Usually manifests as a single skin nodule caused by microfilaria and trapped by the immune system and lung parenchymal disease. In many cases, pulmonary and subcutaneous lesions are misidentified as malignant tumors, requiring surgery before the correct diagnosis is made. Subcutaneous migration of the worm cause local painful swelling with changing localization. Most commonly affected areas are face, lids, chest, wall, upper arms, thighs, male genitalia and abdominal wall. The first human case of *Dirofilaria repens* infection was recorded in Latvia in 2010 (Dissanaike, Abeyewickreme, Wijesundera, Weerasooriya, Ismail, 1997; Gtierrez, 1984; Pampiglione, Rivasi, Angeli, 2000).

MATERIALS AND METHODS

Blood samples from dogs were collected from 2008 to 2011. A total of 4122 stabilized blood samples with coagulant EDTA were analyzed. Samples were collected from Riga, Riga region and few from other regions of Latvia. Blood samples from dogs were collected at small animal veterinary clinics and sent to the laboratory for hematological analysis within 24 h in ice box. Samples from regions of Latvia were sent to laboratory within one week with special laboratory car. Until forwarding to laboratory samples hold in refrigerator.

Blood smear: Blood films were made by placing a drop of blood on one end of a slide, and using a spreader slide to disperse the blood over the slide's length to obtain a monolayer, where the cells are spaced far enough apart to be counted and differentiated (Ettinger, Feldman, 1995)

The slide was left to air dry, after which the blood was fixed to the slide by immersing briefly in methanol to ensure good staining and presentation of cellular details. After fixation, the slides were stained to distinguish the cells from each other.

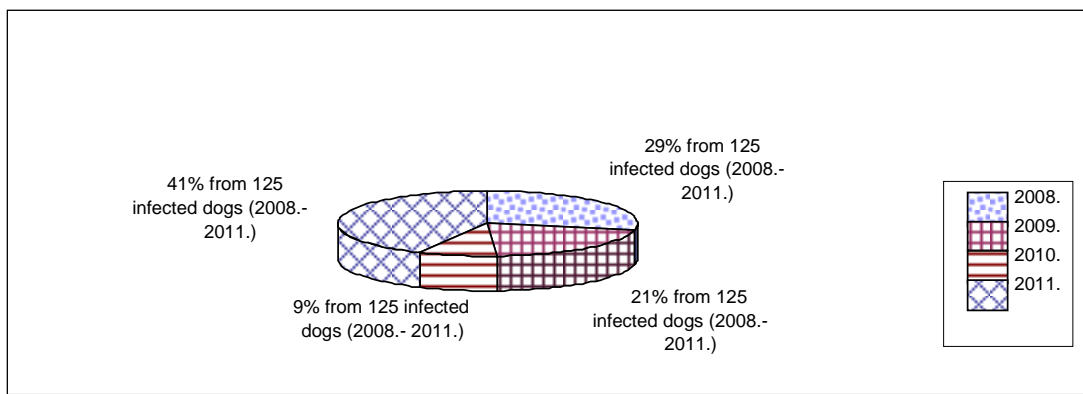
Slides were stained with MGG QUICK STAIN (BIO Optica Milano s.p.a., Italy). Solutions of the kit contained the same dye as traditional May Grunwald and Giemsa solutions. Before stain smears were dried in the air, slides were immersed 5 times for 1 second in solution "B" and to drain off unnecessary solution. Afterwards, slides were immersed twice for a one second in solution "C", then rinsed in distilled water and left to air dry. After staining, the monolayers were viewed under microscope (Nikon Eclipse E-400, Japan).

KNOTT test: A total of 9 ml of 2% formalin were added to 1 ml of freshly drawn blood in a 12 ml centrifuge tube and mixed to lyse red blood cells. The tubes were centrifuged for a ten minutes at 1500 rpm. After centrifugation supernatant was taken off to 0,5 ml. A total three drops of methylene blue were added to sediment. Then stir or mix up the sediment in the bottom of the tube. Left approximately 15 minutes so that sediment settle down after mix. Put 13µl to slide and cover with cover-slip and examine under microscope.

RESULTS AND DISCUSSION

The highest prevalence of *Dirofilaria* spp. (41%) was observed in 2011, whereas during years 2008-2010, prevalence varied between 9 and 29%.

Overall, 125 samples (3%) were found positive for the presence of *Dirofilaria* spp. (Figure 1). Microfilaria were detected in dogs permanently staying outdoors, while the incidence of infected dogs increased in spring and autumn, when the mosquito feeding activity was supposed to be the highest.



1. attēls. Invadēto suņu kopskaita sadalījums pa gadiem
Figure 1. Total infected dogs distributed by years

1. tabula / Table 1

Izmeklēto suņu skaits sezonās un pozitīvie gadījumi
Number of investigated dogs in quarter and positive cases

Quarter	Months	2008		2009		2010		2011		Total	
		Total	Positive (%)	Total	Positive (%)	Total	Positive (%)	Total	Positive (%)	Total	Positive (%)
Winter	December, January, February	238	6 (2,5)	200	7 (3,5)	218	1 (0,5)	261	4 (1,5)	907	18 (2)
Spring	March, April, May	232	12 (5,2)	303	6 (2)	269	6 (2,2)	306	15 (4,9)	1110	39 (3,5)
Summer	June, July, August	192	3 (1,6)	264	7 (2,7)	237	2 (0,8)	350	19 (5,4)	1043	31 (3)
Autumn	September, October, November	231	14 (6,1)	247	6 (2,4)	276	2 (0,7)	308	15 (4,9)	1062	37 (3,5)

Dogs in the age group 6-9 were most often become infected with *Dirofilaria* spp. There is needs a deeper investigation to understand, why this age group is under the risk.

**Invadēto suņu skaits ņemot vērā vecuma grupas
Years group and number of invadeted dogs**

Age	No. of infected dogs in 2008	No. of infected dogs in 2009	No. of infected dogs in 2010	No. of infected dogs in 2011	Total
0- 2	3	1	4	2	10
3- 5	6	5	3	15	29
6- 9	12	14	1	19	46
10- 13	12	3	3	17	35
over 14	2	2	0	1	5

In our samples from infected dogs breed we found, in first place are metis and German shepherd dog. Statistical lower with *Dirofilaria* spp. infected are small dogs. During 2008 to 2011 were infected only 4 small dogs (Cocker spaniel, Toy terrier, West Highland white terrier and Yorkshire terrier). But in risk group are all large size dogs.

**Invadēto suņu šķirnes
Breed of invadeted dogs**

Breed	Total	Breed	Total
Metis	40	Tibetan Mastiff	1
German Shepherd dog	29	Beagle	1
Rottweiler	9	Keeshond	1
Bernese Mountain dog	5	Toy Terrier	1
Labrador	5	Collie	1
Shar Pei	4	Laika	1
Irish setter	3	Dobermann	1
Boxer	3	Akita	1
Caucasion Shepherd dog	2	Newfoundland	1
Dalmatian	2	German Bird hound	1
Central Asian Shepherd dog	2	Bulldog	1
Canadian Shepherd dog	2	West Highland White Terrier	1
Cocker Spaniel	1	Yorkshire Terrier	1
Golden retriever	1	Bullmastiff	1
Malamute	1	St. Bernardshund	1

CONCLUSION

1. Mostly with *Dirofilaria* spp. infected were metis and large size dogs, like German shepherd dog, Rottweiler, who mostly lives outside households and are bitted with mosquito.
2. Microfilarias were detected mostly in spring and autumn because these periods coincide with larva migration in dog's blood.
3. Further investigations are needed to study the risk age group of dogs (6 to 9 years old) and clarify which the *Dirofilaria* species are predominant in Latvia.

ACKNOWLEDGEMENT

I want to say thanks to all my colleagues in Scientific Institute “BIOR”, who helps me with my work and will help in the future. And special thanks to my colleagues Maruta Bunkse and Dina Cirule and my supervisor Muza Kirjusina. I would like to acknowledge Aivars Berzins for his practical advices and support during preparation of my publication and English translation.

REFERENCES

1. Anderson, R.C., Nematode Parasites of Vertebrates, Their Development and Transmission. - 2nd 2000; 482 - 87.
2. Dissanaïke, A.S., Abeyewickreme, W., Wijesundera, M.D., Weerasooriya, M.V., and Ismail, M.M. Human dirofilariasis caused by *Dirofilaria (Nochtiella) repens* in Sri Lanka. - Parassitologia 1997; 39: 375 - 382.
3. Ettinger, Stephen, J. Feldman, Edward, C. Textbook of Veterinary Internal Medicine (4th ed.). 1995; 233.
4. Gtierrez, Y. Diagnostic features of zoonotic filariae in tissue sections. - Hum Pathol. 1984; 15: 514- 25.
5. Heartworm Disease: Introduction in the Merck Veterinary Manual, Ninth Edition, 2006.
6. Marquardt, W.C., Demaree, R.S., Grieve, R.B., Parasitology Vector & Biology - Second Edition. 2000, 464- 71.
7. Marty, A.M., Neafie, R.C., Dirofilariasis. In Mayers W.M., editor. Pathology of infectious diseases. Volume I, Helminthiases. Washington: American Registry of Pathology; 2000; 275 - 85.
8. Pampiglione, S., Rivasi, F. Human dirofilariasis due to *Dirofilaria (Nochtiella) repens*: an update of world literature from 1995 to 2000. Parassitologia. 2000; 42: 231 - 54.
9. Pampiglione, S., Rivasi G., Angeli et al. Dirofilariasis due to *Dirofilaria repens* in Italy, an emergent zoonosis, report of 60 new cases. Histopathology, 2000; 38 (4): 344 - 354.
10. Rafiee, M. Study of Prevalence of *Dirofilaria immitis* Infestation in Dogs were examined in Veterinary Clinics of Tabriz Azad University (Iran) during 1992–2002. 2005; 1-7.
11. Tarello, W. Clinical Aspects of dermatitis Associated with *Dirofilaria repens* in Pets: A Review of 100 canine and 31 Feline Cases (1990 - 2010) and a Report of a new clinic Case Imported from Italy to Dubai. Report 2011; 1 - 5.
12. Taylor, M.A., Coop, R.L., Wall, R.L., Veterinary parasitology - Third Edition. 1987; 411-14, 435, 756 - 57, 778- 80.
13. Zinčenko, L., Krūmiņa, A., Cīrule, K., Stepaņana, L., Kirjušina M. Cilvēka dirofilariozes klīniskā gadījuma analīze. - RSU Zinātniskas konferences tēzes. 2012; 192.