

EFFECTS OF ACEPROMAZINE MALEATE ON INTRAOCULAR PRESSURE AND PUPIL DIAMETER IN DOG'S EYE

Līga Kovaļčuka, Edīte Birģele

Latvia University of Agriculture
e-mail: kovalcuka@gmail.com

Abstract

The research was performed at the Faculty of Veterinary Medicine of the Latvia University of Agriculture. At the moment the research in veterinary anesthesia is in its infancy stage. The aim of this study was to determine the effects of the acepromazine maleate on intraocular pressure (IOP) and horizontal pupil diameter (HPD) in a dog's eye. Ten adult dogs of different age, breed and sex were examined clinically and ophthalmologically. All animals were clinically and ophthalmologically healthy. Animals received acepromazine intramuscularly. IOP and HPD were measured every 5 minutes for the total period of 60 minutes.

It was established that the acepromazine maleate intramuscular injection causes an IOP decrease in both eyes. A significant IOP decrease was observed from 35 till 60 minutes after the acepromazine injection. The pupil constriction was observed 5 minutes after the treatment and continued to contract till the end of the research.

As acepromazine maleate causes a significant decrease of intraocular pressure, it is not contraindicated to be used in the case of corneal trauma, perforation, glaucoma and corneal ulcers.

Key words: dog, eyes, acepromazine maleate, intraocular pressure, horizontal pupil diameter.

Introduction

It is known that the intraocular pressure (IOP) is controlled and regulated by the central nervous system (CNS), that maintains the balance between the aqueous humor production and outflow (Brunson, 1980). Factors like external mechanical pressure, scleral rigidity and intraocular changes, the same as some drugs that influence the production of aqueous humor and outflow, do influence IOP (Cunningham and Barry, 1986). In the case of corneal lesions it is important not to use drugs that can cause an IOP increase, thereby causing a corneal rupture, even iris prolapse (Brooks, 1990; Chmielewski et al., 1997).

Acepromazine maleate is a phenothiazine derivate that is commonly used in small animal premedication to calm the animal and to gain a faster and deeper animal sleep during the narcosis. Acepromazine maleate blocks α – adrenoreceptors in the walls of blood-vessels which causes the dilatation of blood vessels and decreases arterial blood pressure (Muir et al., 1975; Thurmon et al., 1996).

Considering the fact that in literature only few data are found dealing with the effects of acepromazine maleate on the intraocular pressure and pupil diameter in dogs (*canis familiaris*) and animals generally, this research is very actual.

The aim of this study was to determine the effects of acepromazine maleate on the intraocular pressure and pupil diameter in dogs.

Materials and Methods

All animals were out-patients examined at the Preclinical Institute of the Faculty of Veterinary Medicine of the Latvia University of Agriculture in 2008. This study was accepted by the Animal Protection and Ethical Commission of the Latvian State Food and Veterinary Service. In all cases an informed consent was obtained from the pet owners for the study.

All animals included in this study were examined clinically and ophthalmologically. Examination included slit lamp-biomicroscopy, direct ophthalmoscopy and monocular indirect ophthalmoscopy with Pan Optic® (Welch Allyn, USA). The information on the animal breed, age and sex was noted. In this investigation we used ten healthy dogs of different age, breed and sex, all patients were determined to be free of ocular lesions that could alter IOP from normal.

To ascertain the effect of acepromazine maleate on intraocular pressure and pupil diameter in the dog's eye, we injected 1% acepromazine maleate intramuscularly in the dose of 0.1 mg kg⁻¹. The dose of acepromazine maleate was recommended by researchers as suitable for the premedication in dogs (Booth, 1982).

All tonometric measurements were performed by the same person with the rapid and minimal stress - inducing method of rebound tonometry with a tonometer (TonoVet®, Tiolat Ltd. Finland) using values that achieve less than 5% standard deviation. For this tonometer it is

not necessary to use topical anaesthesia. Some authors have noticed that the corneal endothelial and systemic toxicity could occur with a frequent use of topical anaesthesia (Judge et al, 1997; McGee and Fraunfelder, 2007).

The horizontal pupil diameter was measured with Jameson callipers (USA) under fixed day light conditions at the same time of the day. The IOP and HPD were measured every five minutes, for a total period of 60 minutes.

To process the data of this research we used statistical data program MS Excel (Microsoft® Office Excel 2003). To determine the effect of intramuscular acepromazine maleate, arithmetic mean values (X) and standard deviation (SD) of the IOP and HPD were calculated for each eye. Changes in IOP and HPD between the right and left eye and between the pre-treatment and treatment period in the time period were evaluated using a paired two-sample T-test. P - values less than 0.05 were considered to be statistically significant (Arhipova and Băliņa, 2006).

Results and Discussion

At first we estimated the initial position of the animals' eye – IOP before the acepromazine maleate injection. It was established that there was no significant difference between IOP in the right and left eye ($p > 0.05$), that was within a range of 14 ± 2.90 mmHg. Generally these results did not differ from the other author's data where normal IOP ranged between 16.7 ± 4 mmHg and 18.7 ± 5.5 mmHg (Miller et al., 1993; Gellat and MacKey, 1998).

The influence of the acepromazine maleate is shown in Figure 1. First of all, it should be pointed out that the acepromazine maleate injection caused irregular IOP changes in both eyes: in the first five minutes IOP decreased from 14 ± 2.90 mmHg to

12 ± 2.97 mmHg, in next five minutes it increased almost to the pre-treatment level, in 15 minutes of treatment IOP repeatedly decreased, gaining IOP in the right eye 11.5 ± 2.99 mmHg, and 10.6 ± 2.98 mmHg in the left eye ($p < 0.05$). Thus the IOP level remained the same for 20 minutes after the treatment. Twenty five minutes after the injection IOP again significantly increased up to 13.2 ± 3.15 mmHg in both eyes. IOP significantly decreased 30 minutes after the treatment and 35 minutes post-treatment it gained the lowest IOP level 10.2 ± 2.28 mmHg ($p < 0.05$). During the time period from 40 to 50 minutes after the treatment IOP increased a little but did not reach the initial IOP level (Figure 1.); further until the end of the investigation IOP decreased to 9.41 ± 1.71 mmHg ($p < 0.05$). That demonstrates a significant decrease of intraocular pressure.

Therefore, we can consider that the acepromazine maleate intramuscular injection at the dose of 0.1 mg kg^{-1} on the one hand cause fluctuating and irregular IOP changes, on the other - the total tendency is a significant IOP decrease, especially 35 - 60 minutes after the treatment. Unfortunately, we did not find similar data in the literature, to compare with this research. Literature presents data on the influence of 1% topical acepromazine maleate on IOP in monkeys. It was reported that in monkeys without changes in functional parameters of the eye acepromazine did not change IOP but in animals with glaucoma IOP decrease was observed one, four, eight and even 32 hours after topical the acepromazine administration (Hayreh et al., 1991). In dogs after the intramuscular administration of the acepromazine maleate and hydromorphone no significant differences in IOP were recorded 10 and 25 minutes after the treatment (Stephan et al., 2003). Apparently, the hydromorphone has somehow blocked the acepromazine maleate effect on IOP.

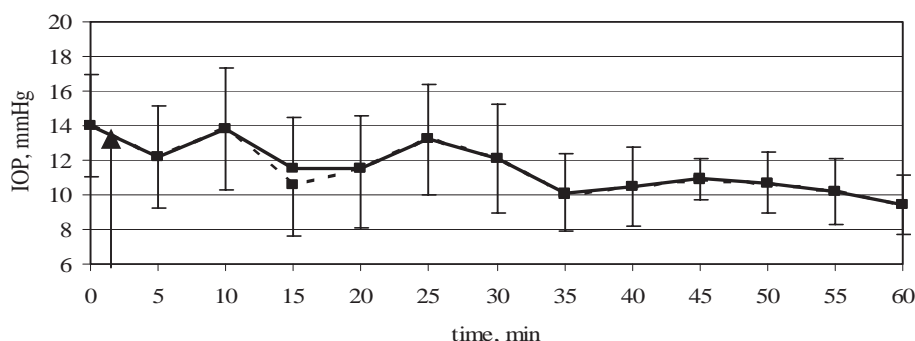


Figure 1. Effects of acepromazine maleate intramuscular injection on intraocular pressure (mean values) in dog's eye : — right eye; left eye; ↑ –time of injection.

The influence of the acepromazine maleate on the horizontal pupil diameter (HPD) is shown in Figure 2.

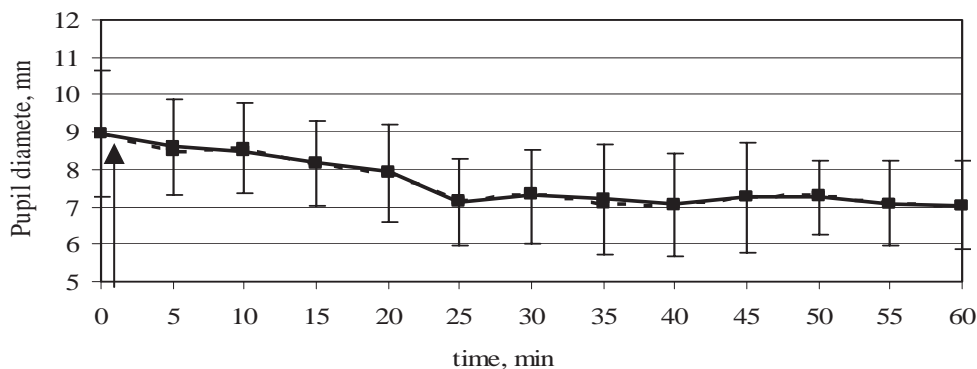


Figure 2. Effects of the acepromazine maleate intramuscular injection on the pupil diameter (mean values) in a dog's eye: — right eye; left eye; ↑ –time of injection.

HPD before the acepromazine maleate injection was on average 8.95 ± 1.67 mm in the right and left eye.

Already five minutes after the acepromazine maleate injection, the horizontal pupil diameter started to decrease gaining 8.6 ± 1.37 mm in the right eye and 8.5 ± 1.29 mm in the left eye. The pupil diameter continued to decrease regularly up to 20 minutes after the treatment, then during next five minutes it decreased to 7.13 ± 1.10 mm in the right eye and 7.18 ± 1.16 mm in the left eye ($p < 0.05$). Starting from the 25th minute the pupil diameter was more or less stable at the level of 7.05 ± 1.16 mm (Figure 2.). During the entire research period the pupil diameter was practically equal in both eyes.

In the above mentioned research where the acepromazine maleate was administered in dogs in the combination with the hydromorphone, the pupil contraction was also established. Significant changes were observed in 16 out of 17 dogs, 25 minutes after the intramuscular injection (Stephan et al., 2003) the same as we observed.

The conclusion may be drawn that the acepromazine maleate intramuscular injection causes a significant pupil contraction, especially 25 minutes after injection.

Conclusions

1. The acepromazine maleate intramuscular injection at a dose of 0.1 mg kg^{-1} , on the one hand causes fluctuating, irregular IOP changes in the dog's both eyes, on the other – the total tendency is a significant IOP decrease, especially 35 - 60 minutes after the injection.

2. In dogs, five minutes after the acepromazine maleate injection the horizontal pupil diameter decreased. The lowest HPD level was obtained 25 minutes after the injection.

3. As the acepromazine maleate decreases the intraocular pressure, its administration is not contraindicated to use the cases of corneal trauma, perforation, glaucoma and corneal ulcers.

References

- Arhipova I., Bāliņa S. (2006) *Statistika ekonomikā un biznesā. Risinājumi ar SPSS un Microsoft Excel (Statistics in economy and business. Solutions with SPSS and Microsoft Excel)*. Datorzinību centrs, Rīga, Latvia, pp. 131-151. (In Latvian).
- Brooks D.E. (1990) Glaucoma in Dog and Cat. *Veterinary Clinical North American Small Animal Practice*, 20, pp. 775-797.
- Booth N.H. (1982) Psychotropic Agents. In: Booth N.H., McDonald L.E (eds) *Veterinary Pharmacology and Therapeutics*, The Iowa State University Press, Ames, Iowa, USA, pp. 321-345.
- Brunson D.B. (1980) Anesthesia in Ophthalmic Surgery. *Veterinary Clinical North American Small Animal Practice*, 10, pp. 481-495.
- Chmielewski N.T., Brooks D.E., Smith P.J., Hendrix D.V.H., Whittaker C., Gelatt K.N. (1997) Visual Outcome and Ocular Survival Following Iris Prolapse in the Horse: a Review of 32 Cases. *Equine Vet J.*, 29, pp. 31-39.
- Cunningham A.J., Barry P. (1986) Intraocular Pressure - Physiology and Implications for Anaesthetic Management. *Canadian Anaesthetists' Society Journal*, 33, pp. 195-208.

7. Gelatt K.N., MacKay E.O. (1998) Distribution of Intraocular Pressure in Dogs. *Veterinary Ophthalmology*, 1, pp. 109-114.
8. Hayreh S.S, Kardon R.H, McAllister D.L, Fleury P.J. (1991) Acepromazine. Effects on Intraocular Pressure. *Archives Ophthalmology*, 109(1), pp. 119-24.
9. Judge A.J., Najafi K., Lee D.A., Miller K.M. (1997) Corneal Endothelial Toxicity of Topical Anesthesia. *Ophthalmology*, 104, pp. 1373-1379.
10. McGee H.T., Fraunfelder F.W. (2007) Toxicities of Topical Ophthalmic Anesthetics. *Expert Opinion on Drug Safety*, 6, pp. 637-640.
11. Miller P.E., Pickett J.P., Majors L.J., Kurzman I.D. (1993) Clinical Comparison of the Mackay-Marg and Tonopen Applanation Tonometers in the Dog. *Progress in Veterinary and Companion Ophthalmology*, 3, pp. 67-73.
12. Muir W.W., Werner L.I., and Hanalin R.I. (1975) Effects of Xylazine and Acerylpromazine Upon Induced Ventricular Fibrillation in Dogs Anesthetized with Thimaylal and Halotan. *American Journal of Veterinary Research*, 36, pp. 1299-1303.
13. Stephan D.D., Vestre W.A., Stiles J., Krohne S. (2003) Changes in Intraocular Pressure and Pupil Size Following Intramuscular Administration of Hydromorphone Hydrochloride and Acepromazine in Clinically Normal Dogs. *Veterinary Ophthalmology*, 6, pp. 73-76.
14. Thurmon J.C., Tranquilli W.J., Benson G.J. (1996) *Veterinary Anesthesia 3rd edition*, William&Wilkins, Baltimore, USA, 184 p.